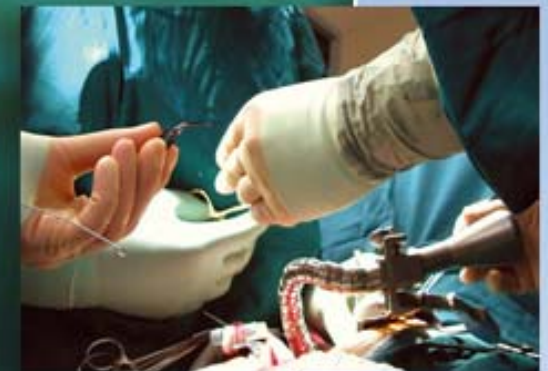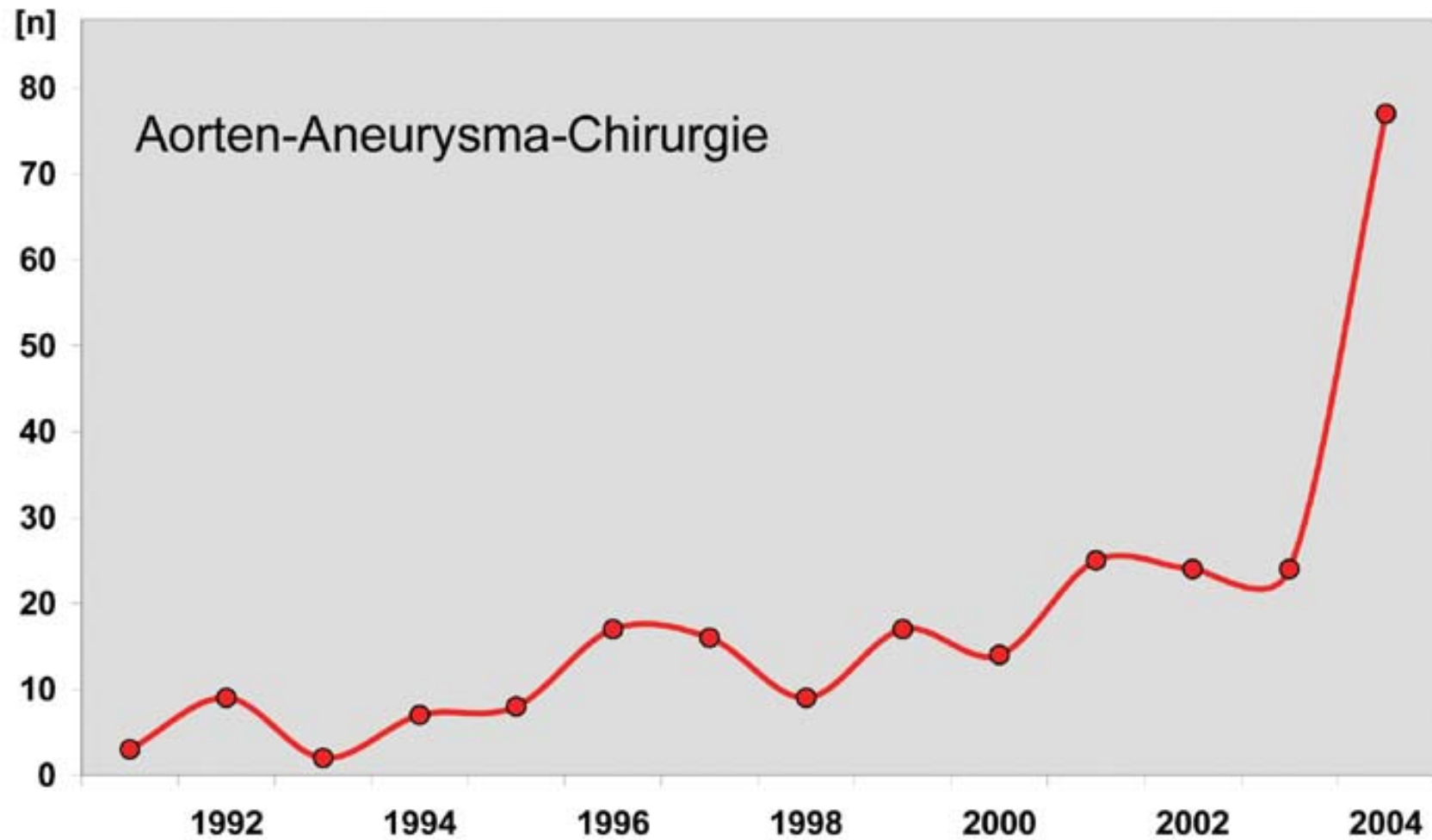


# Hybridbehandlung von komplexen Aortenaneurysmen und Stanford B Dissektionen mit der E-vita open Prothese

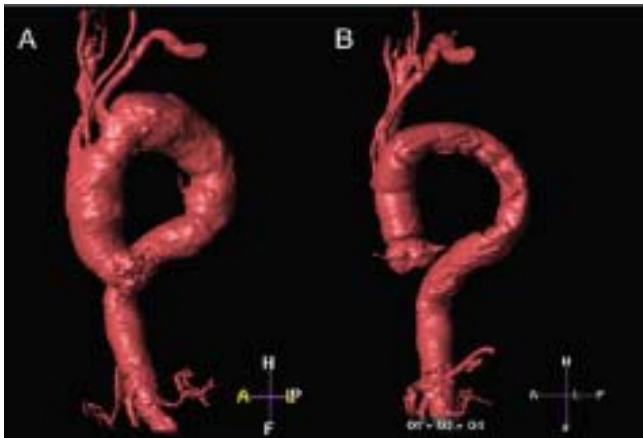
Friedrich-Christian Rieß  
Albertinen Herzzentrum, Hamburg



## Aorten-Aneurysma-Chirurgie

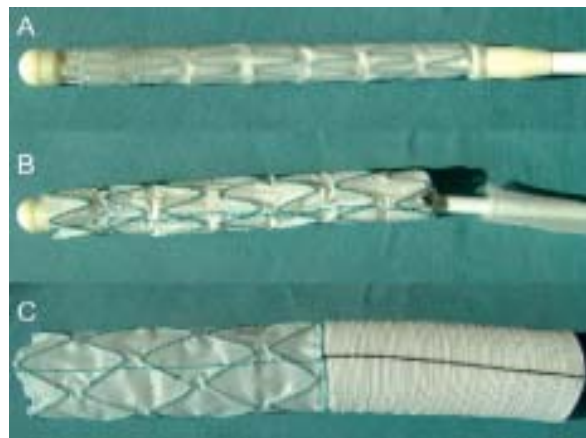


## Aneurysmachirurgie und endoluminales Stenting

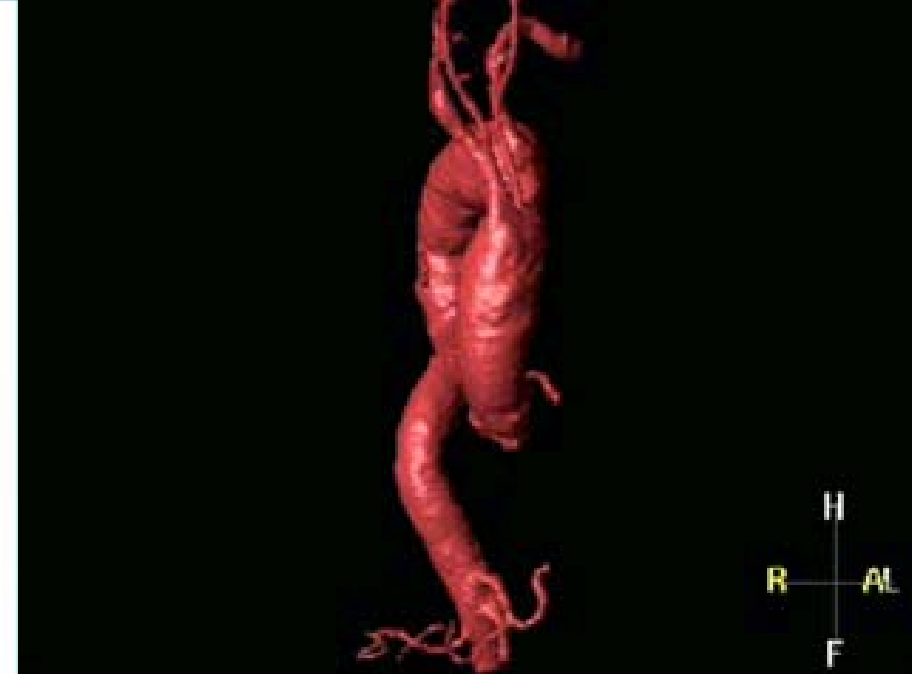

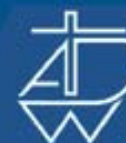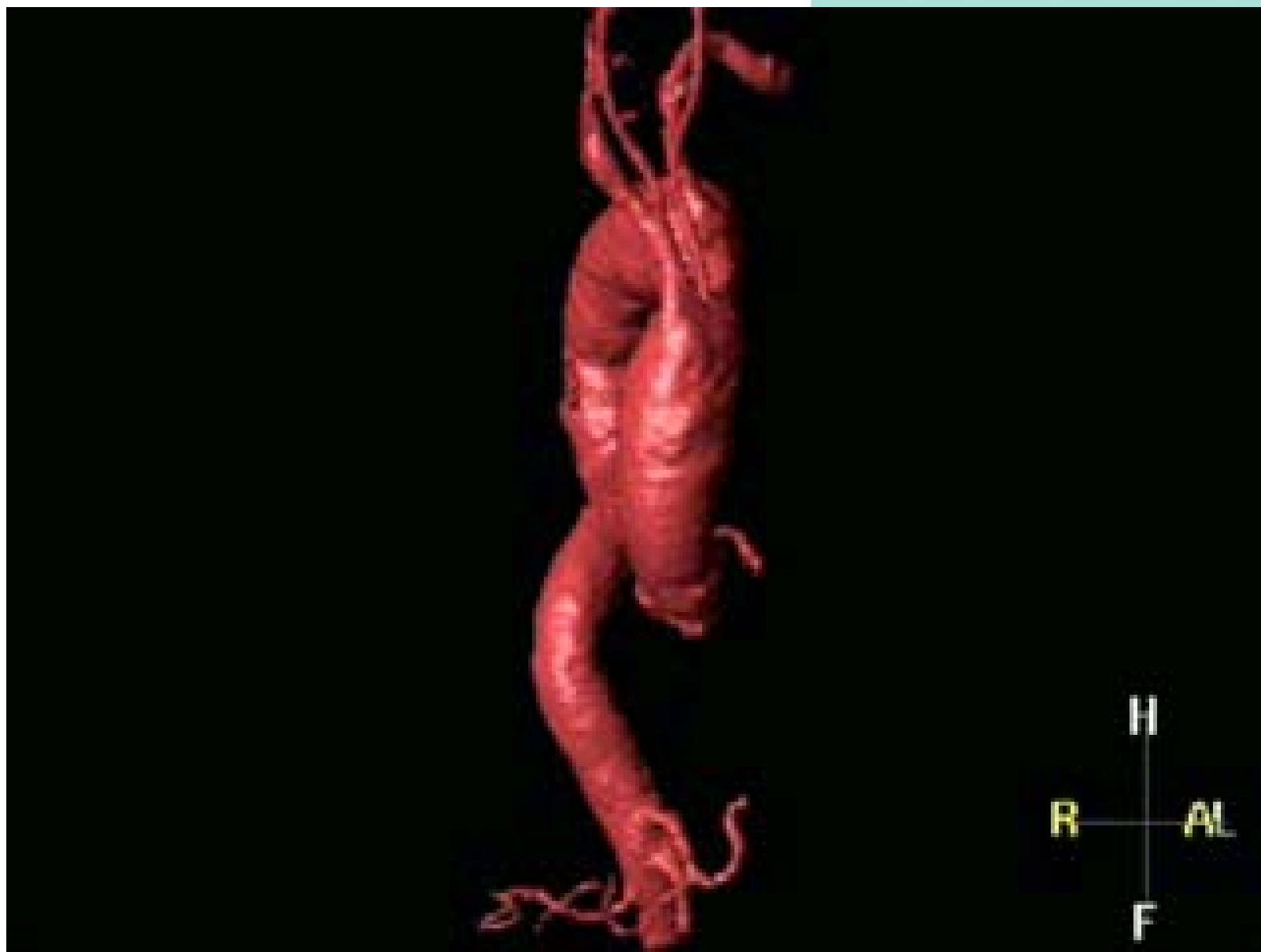Komplexes thorakales Aortenaneurysma vor (A) und nach (B) Hybridaneurysmektomie

Spezialstent für  
Hybridaneurysmektomie  
in verschiedenen  
Entfaltungsphasen

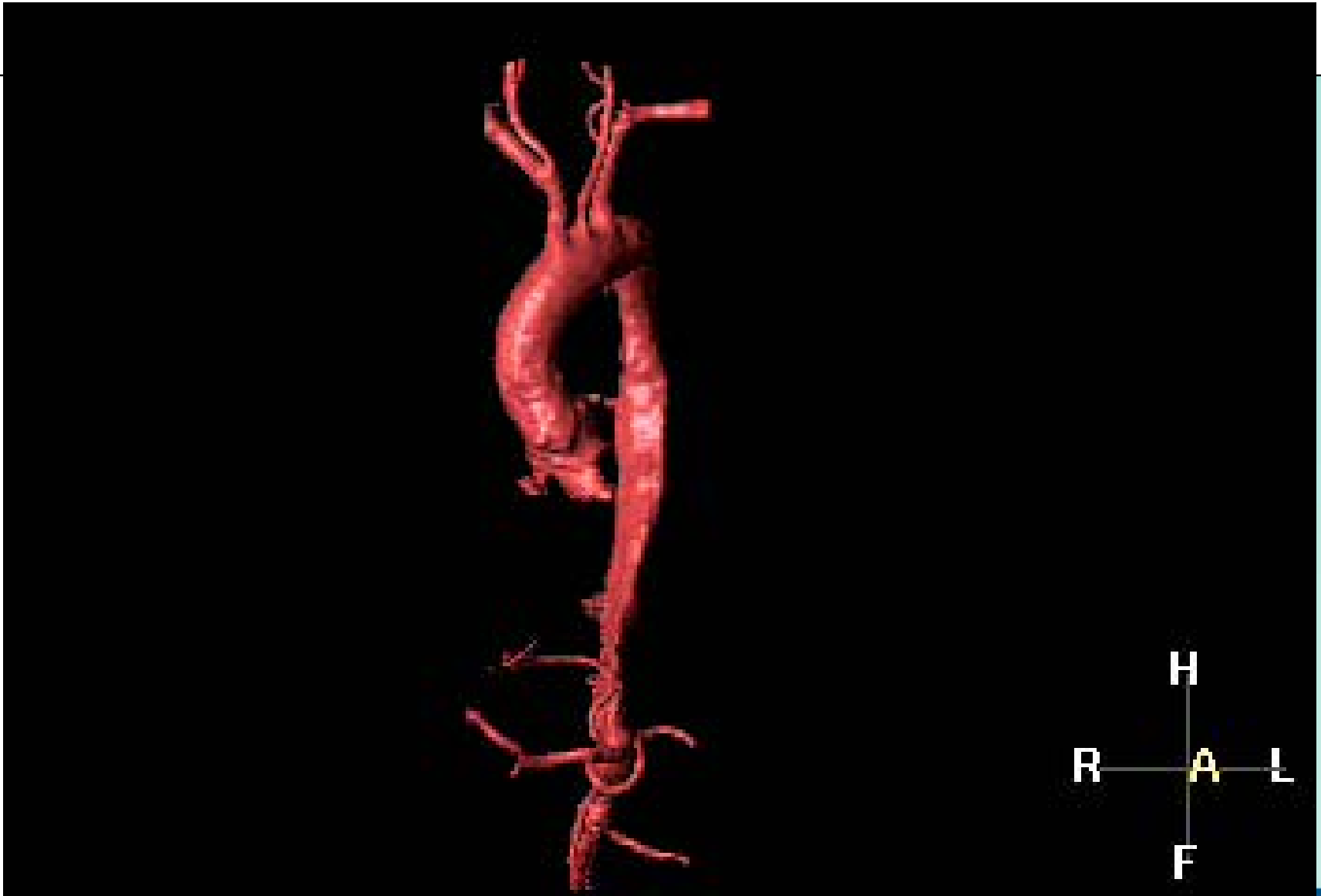

Riess FC, et al. Heart Surgery Forum, in press 2005

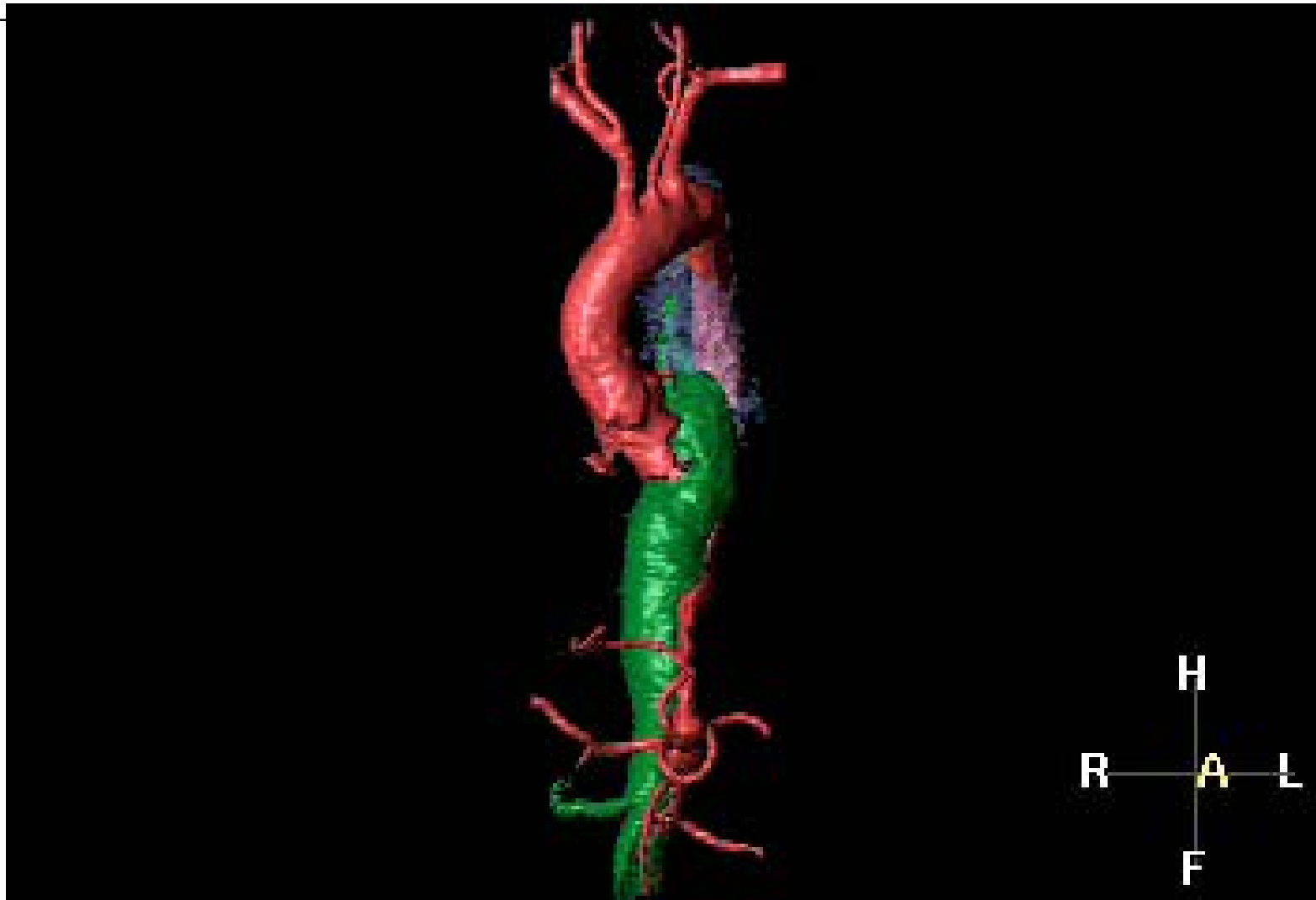




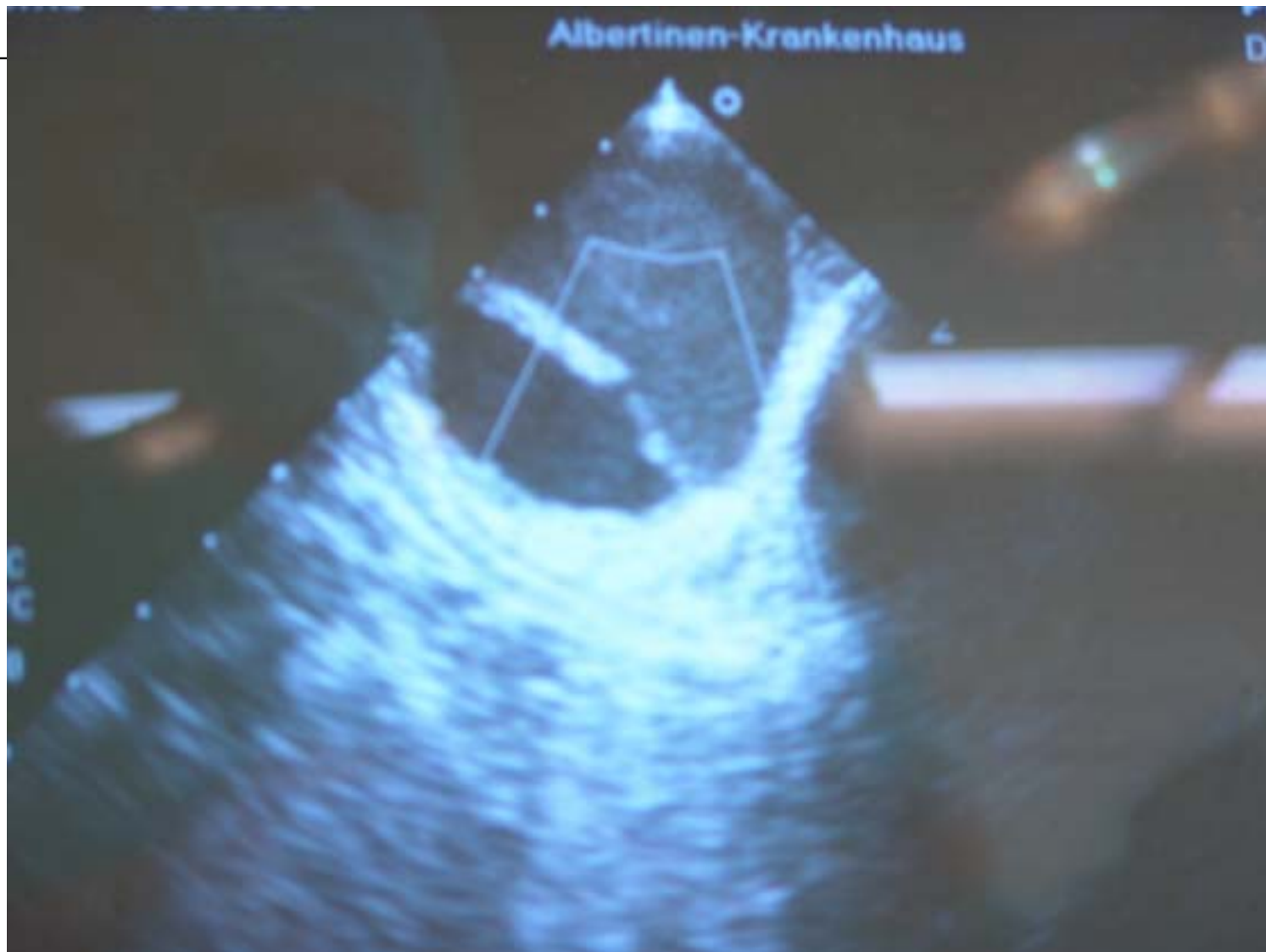## Stanford B Dissection



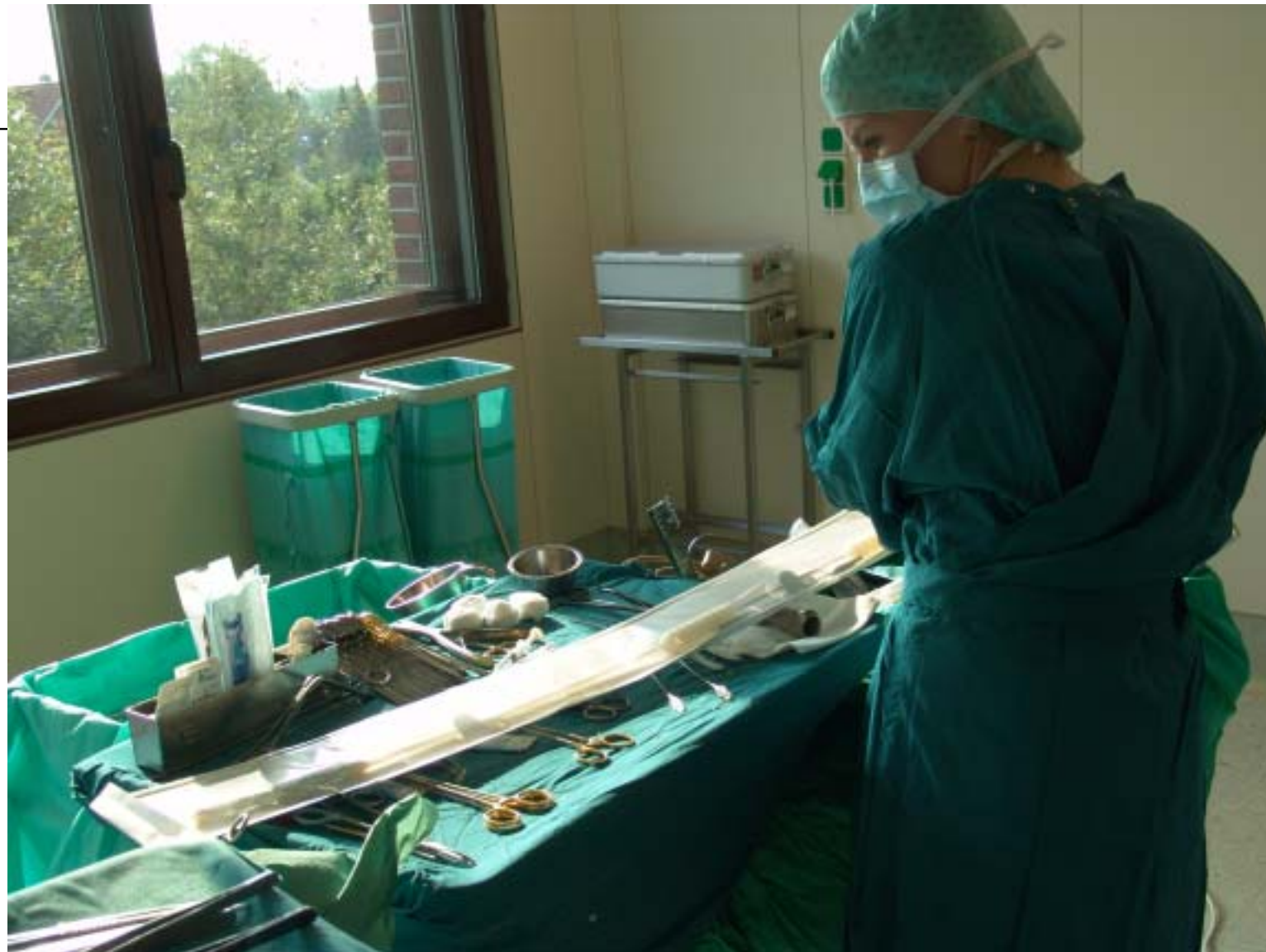## Dissection with Covered Perforation



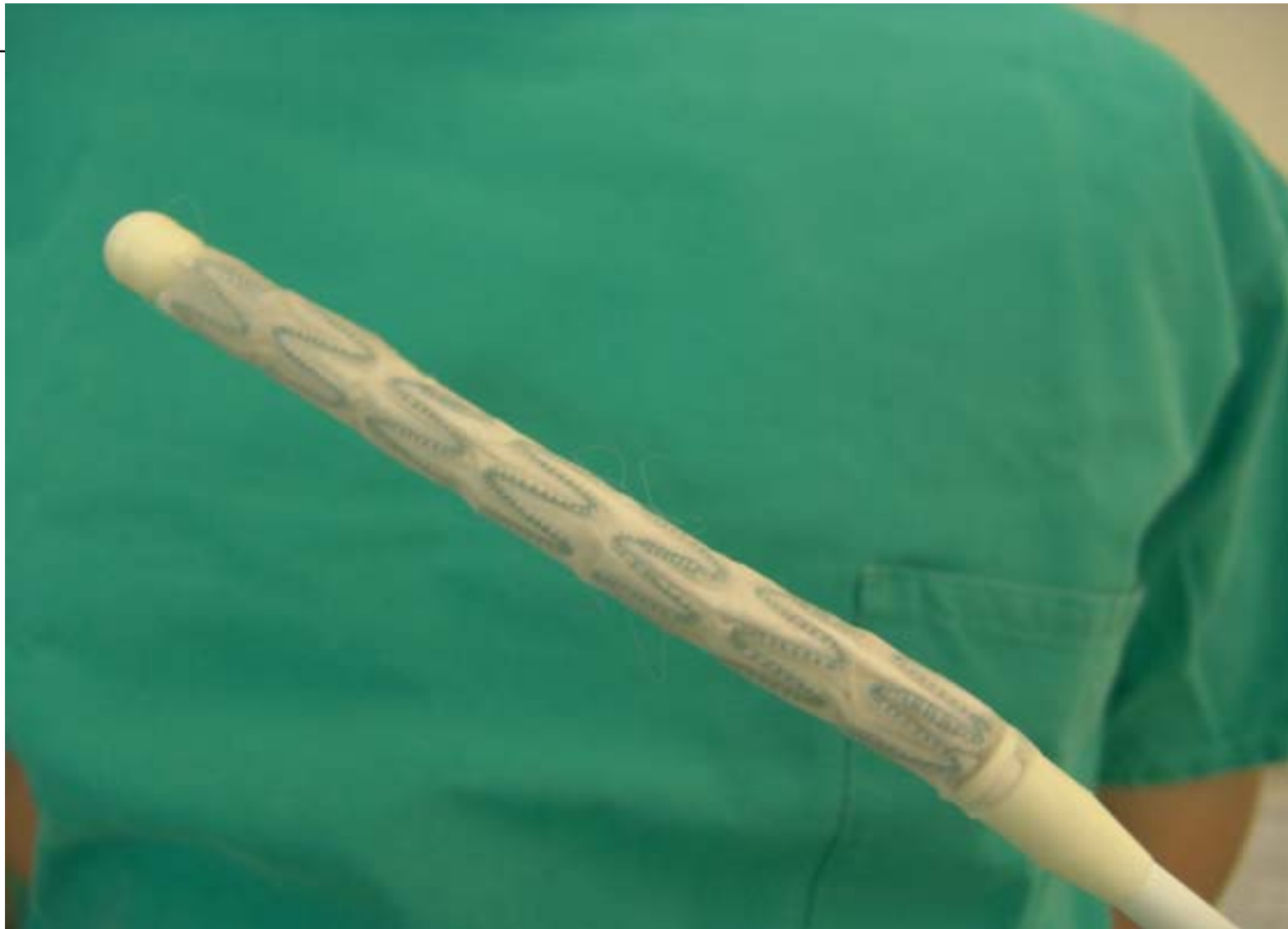## Entry



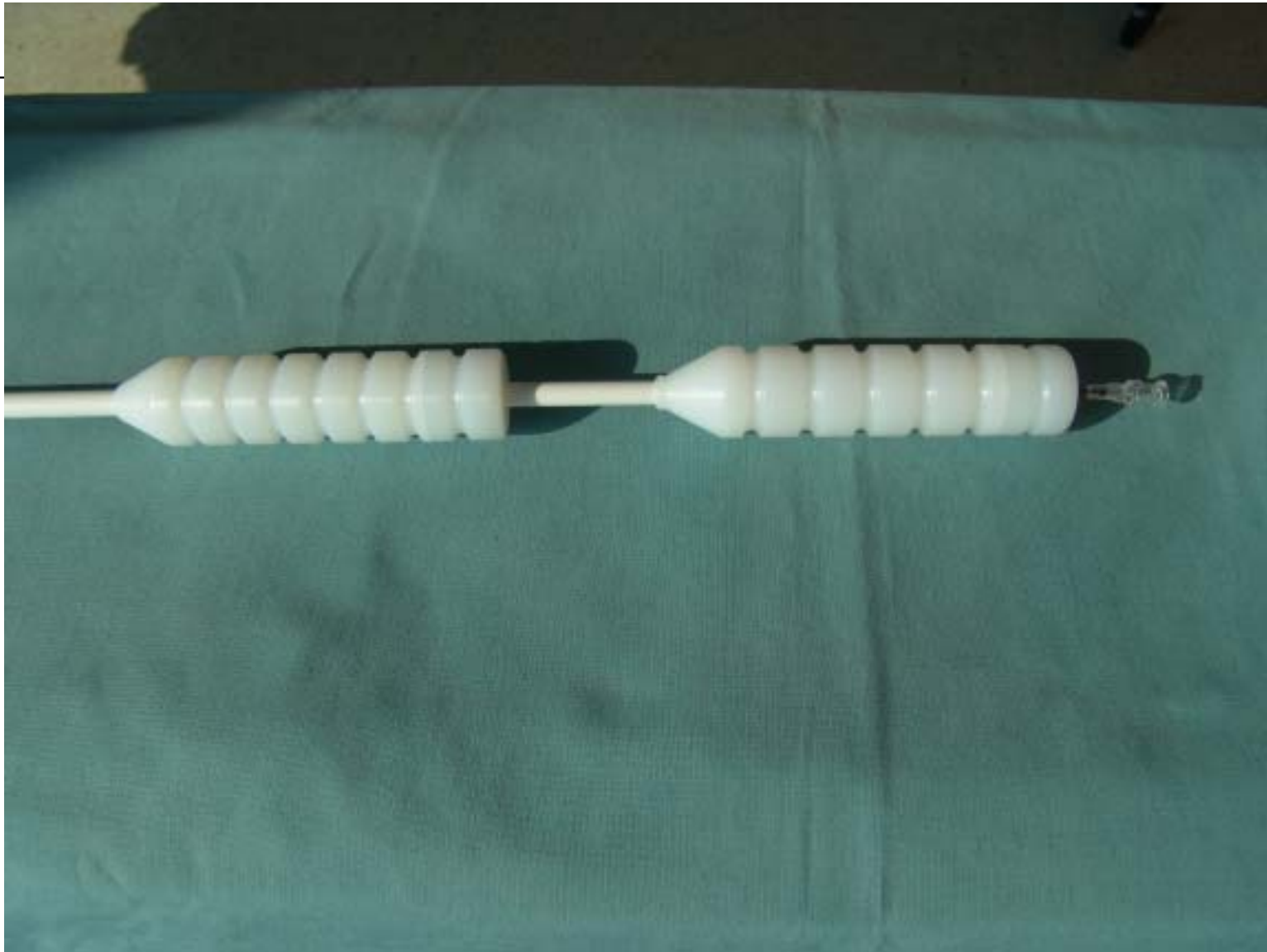## Stent



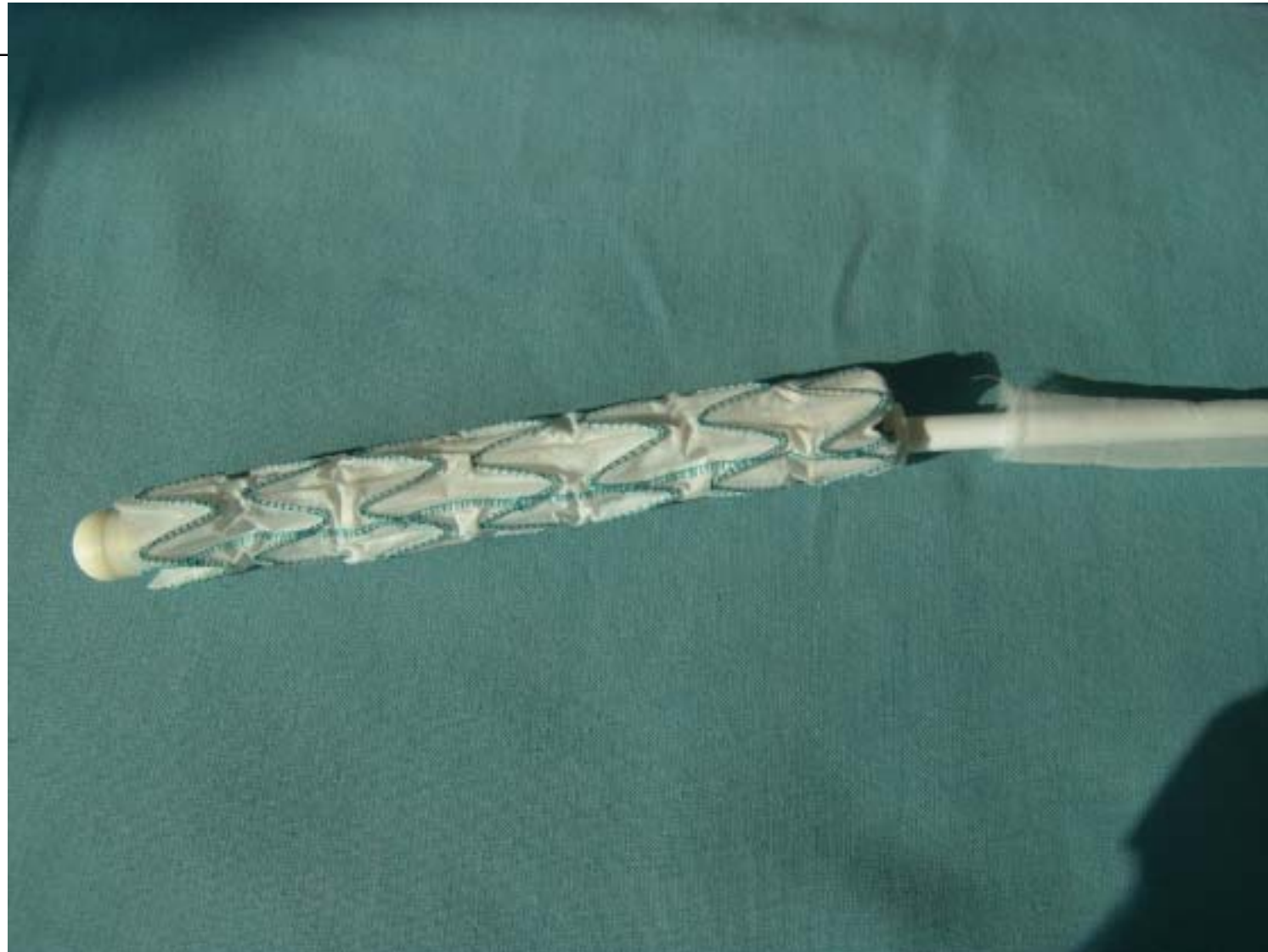
## E-vita open Stent



## Handle of Launching Mechanism

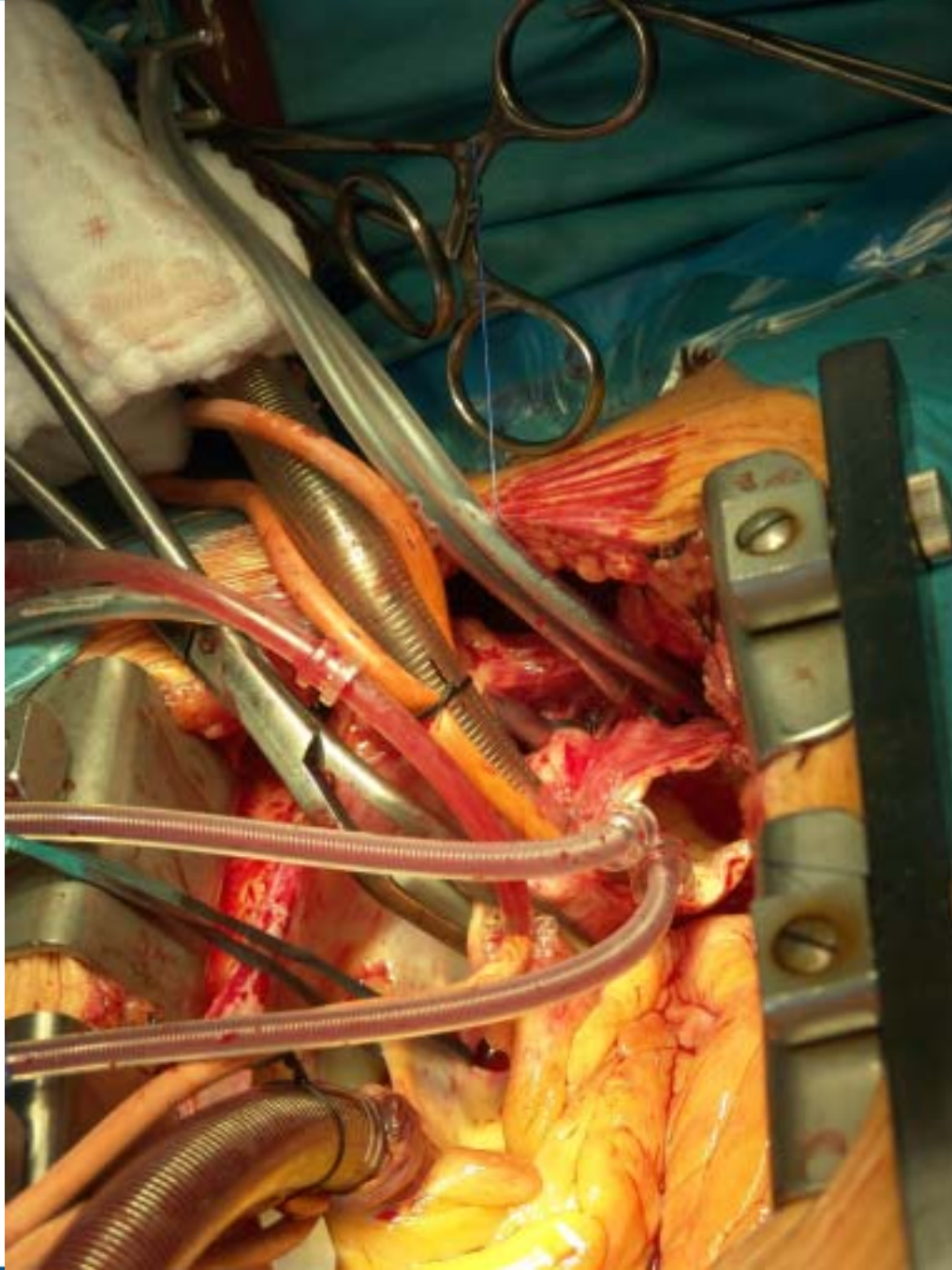


## Launched E-vita open Stent



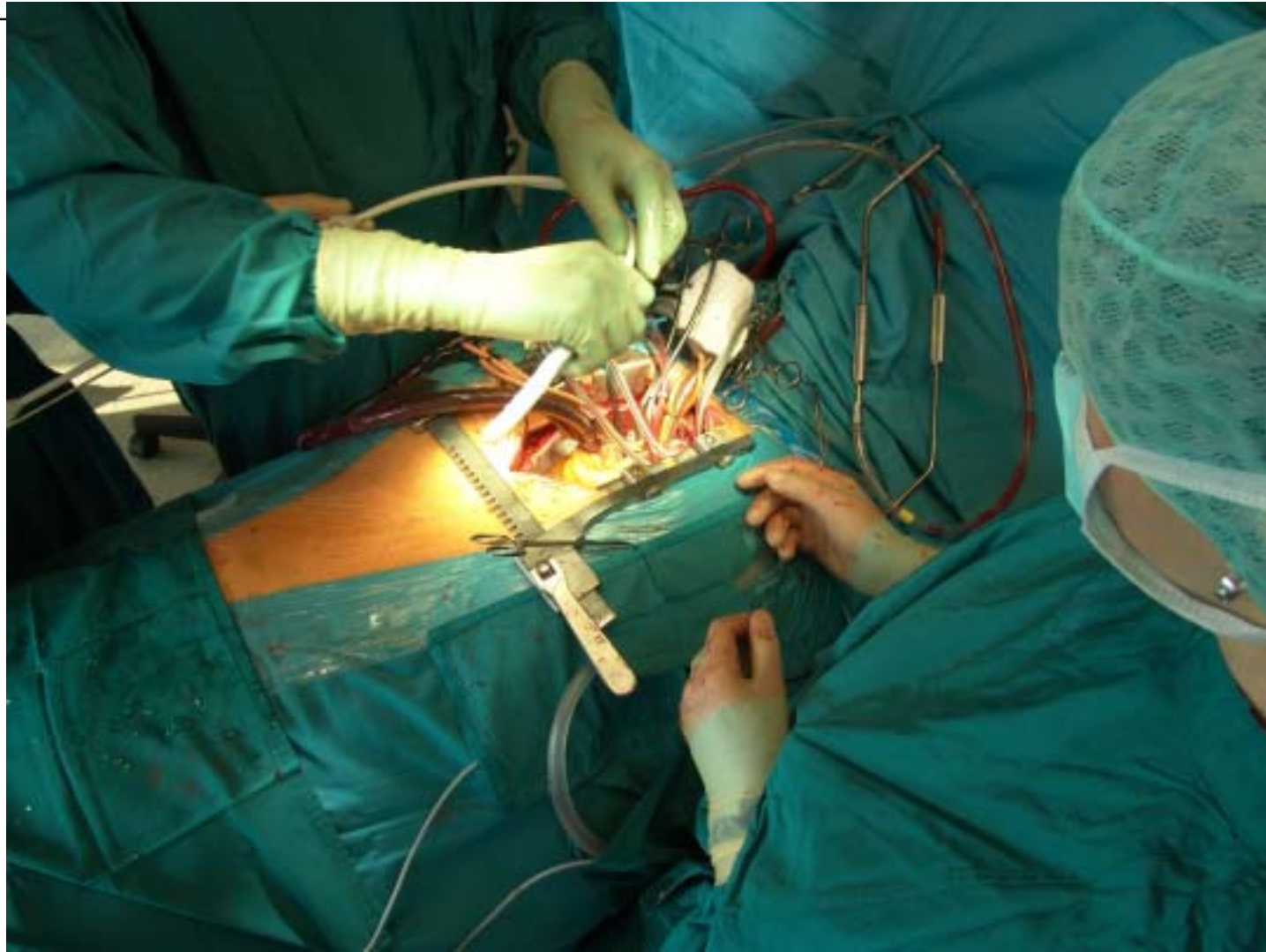
## Expanded E-vita open Stent with Dacron Prosthesis



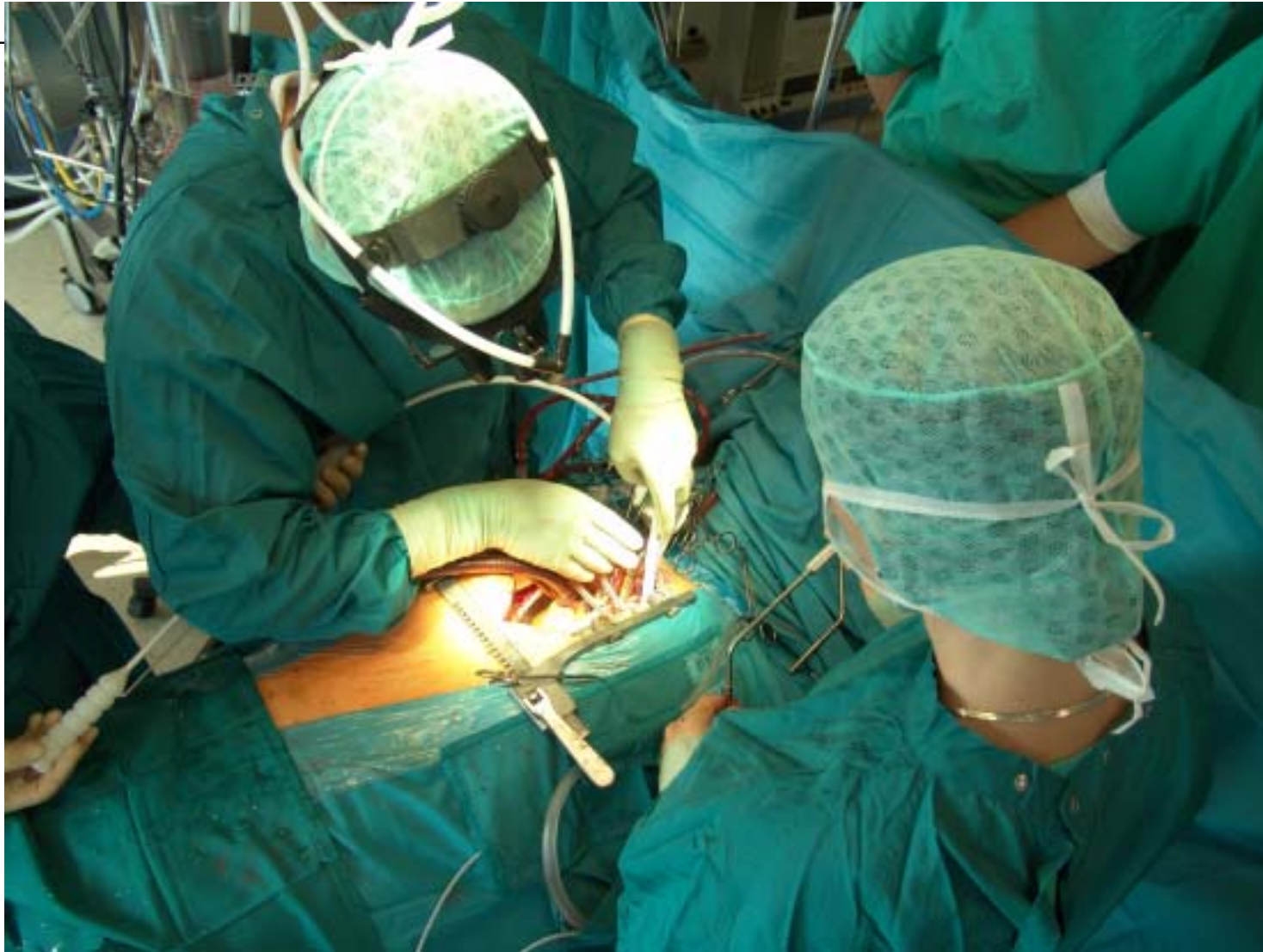

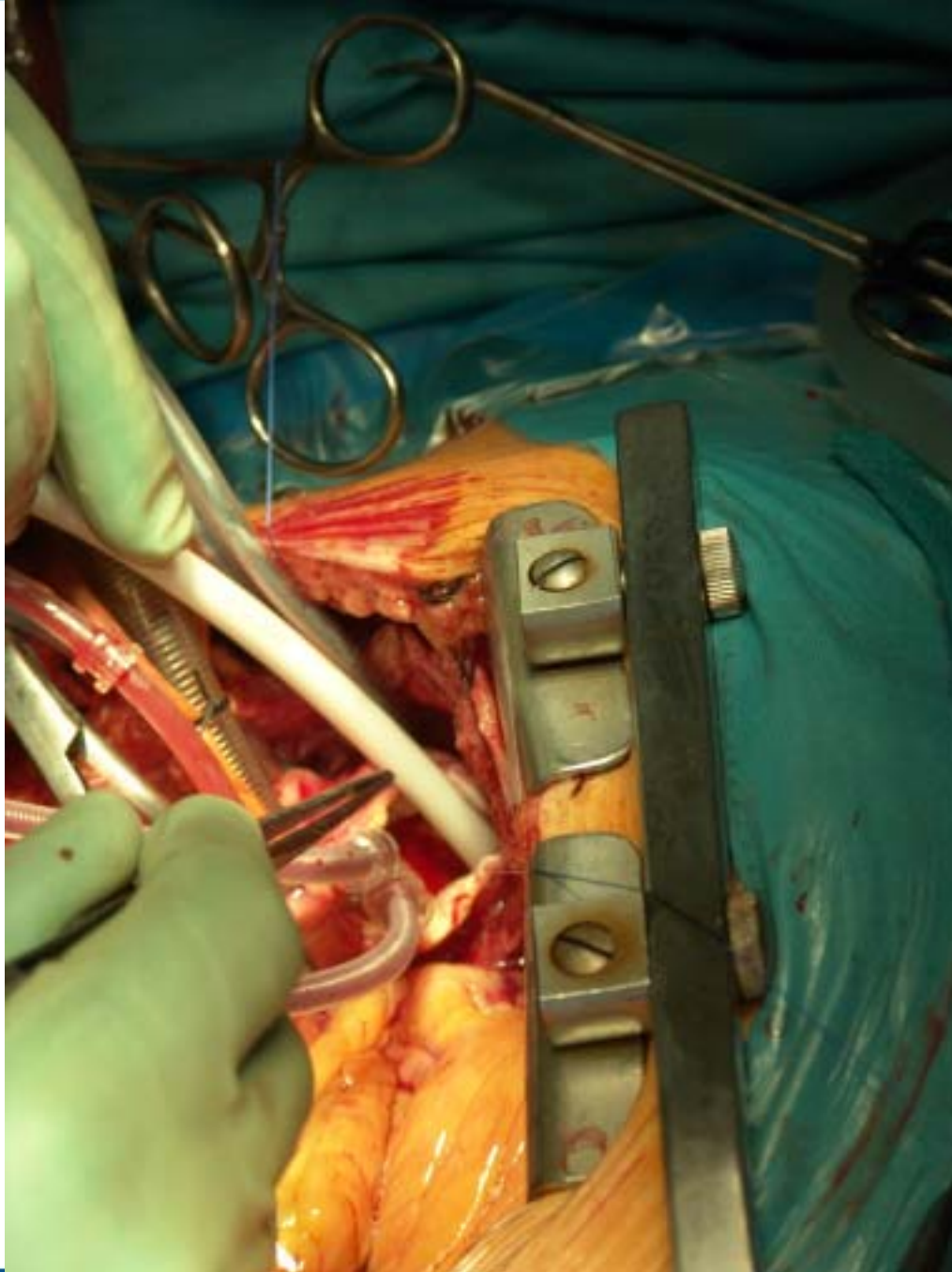
## Circulatory Arrest and Antegrade Brain Perfusion

## Stenting of Descending Aorta

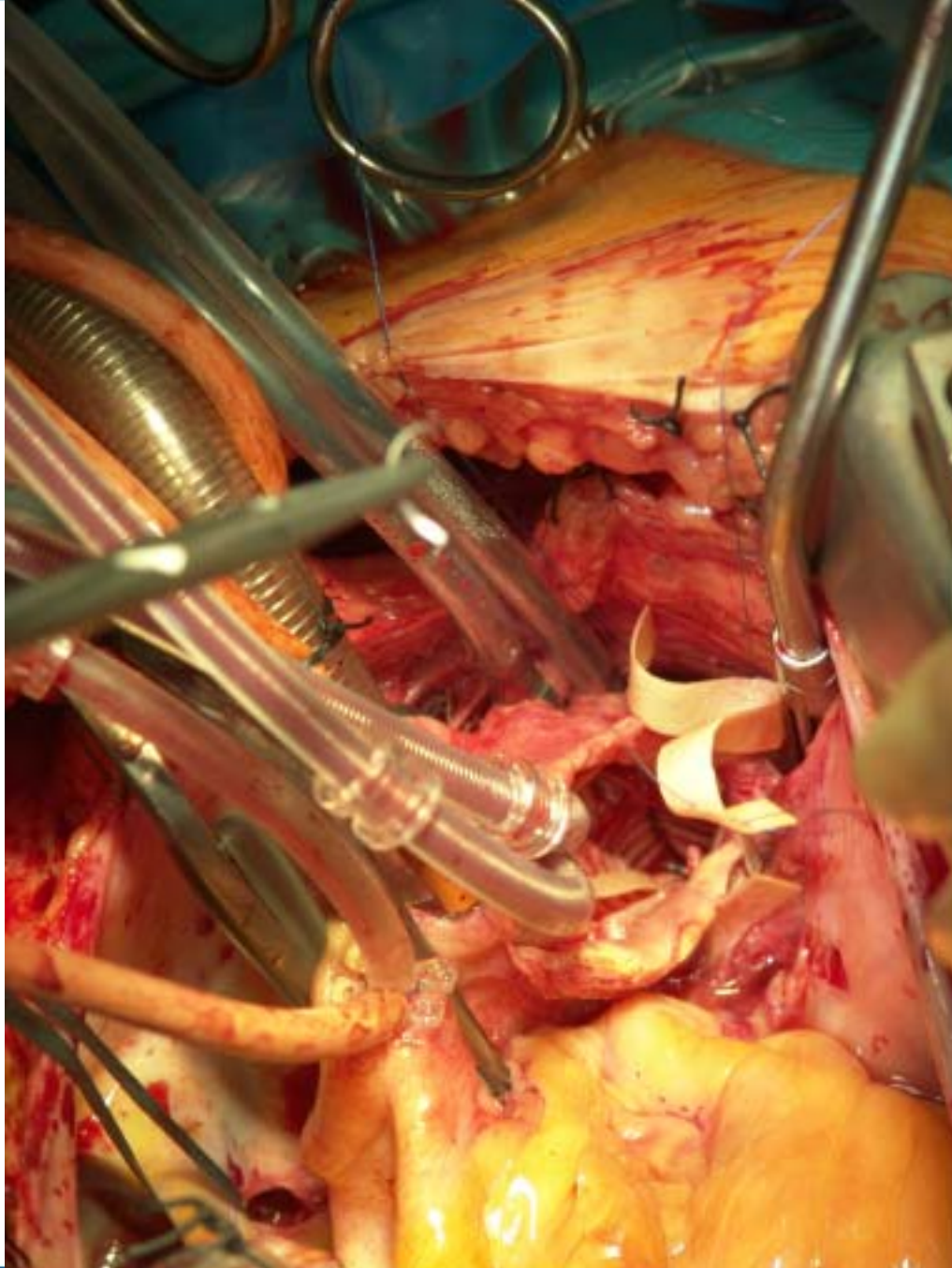


## Stenting of Descending Aorta

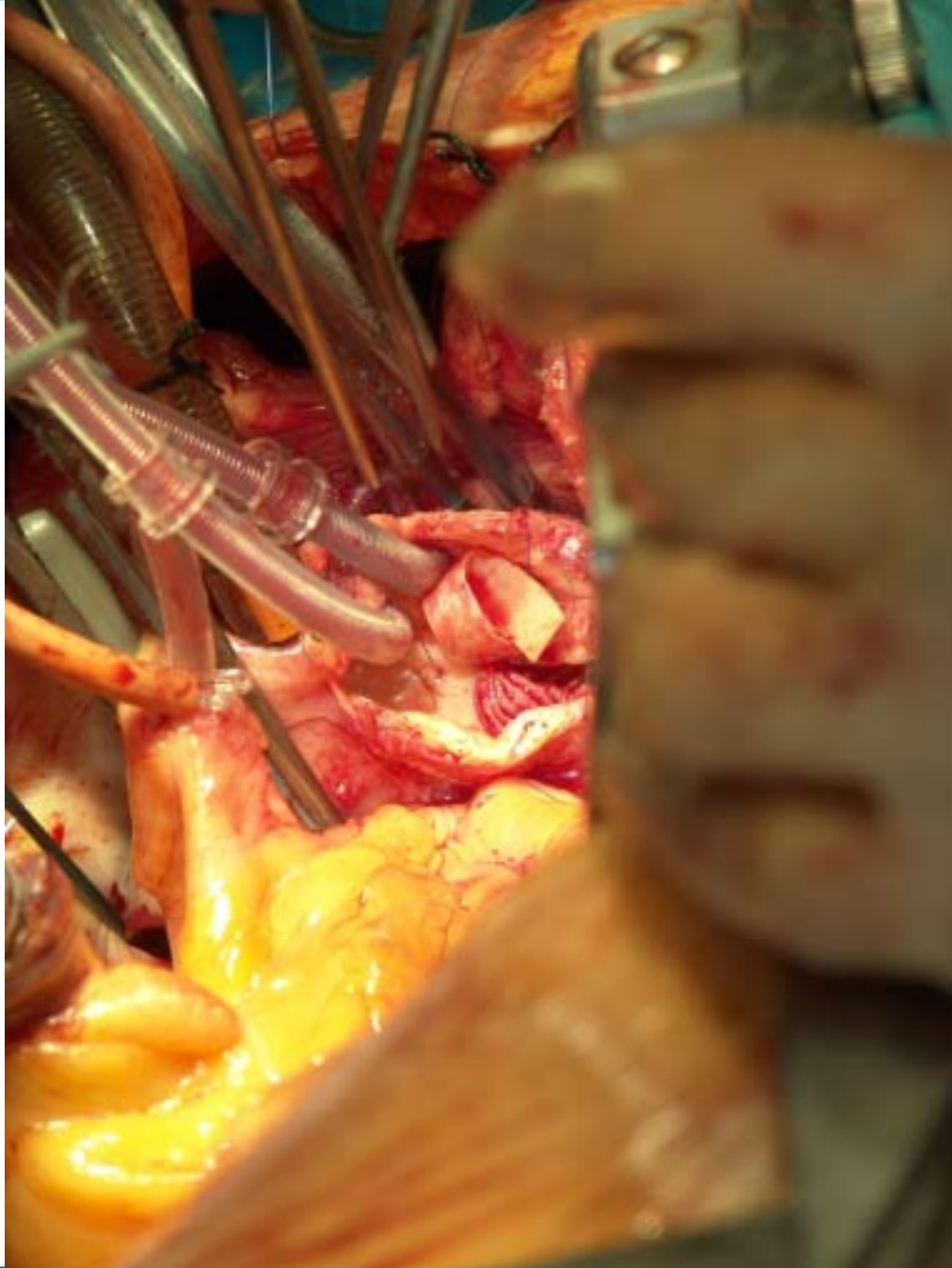



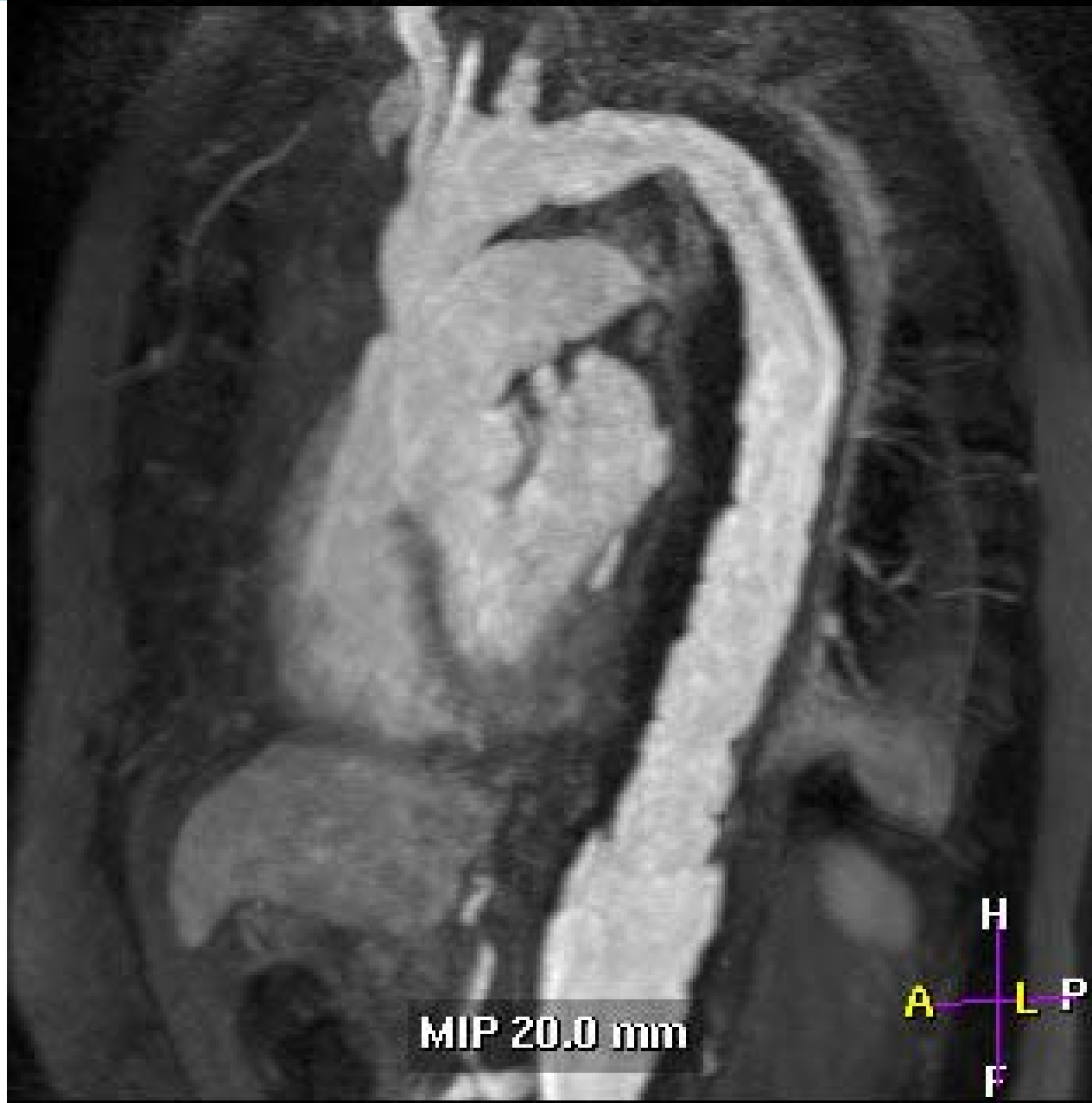## Stenting of Descending Aorta



## Intraluminal Suturing of the Dacron Prosthesis



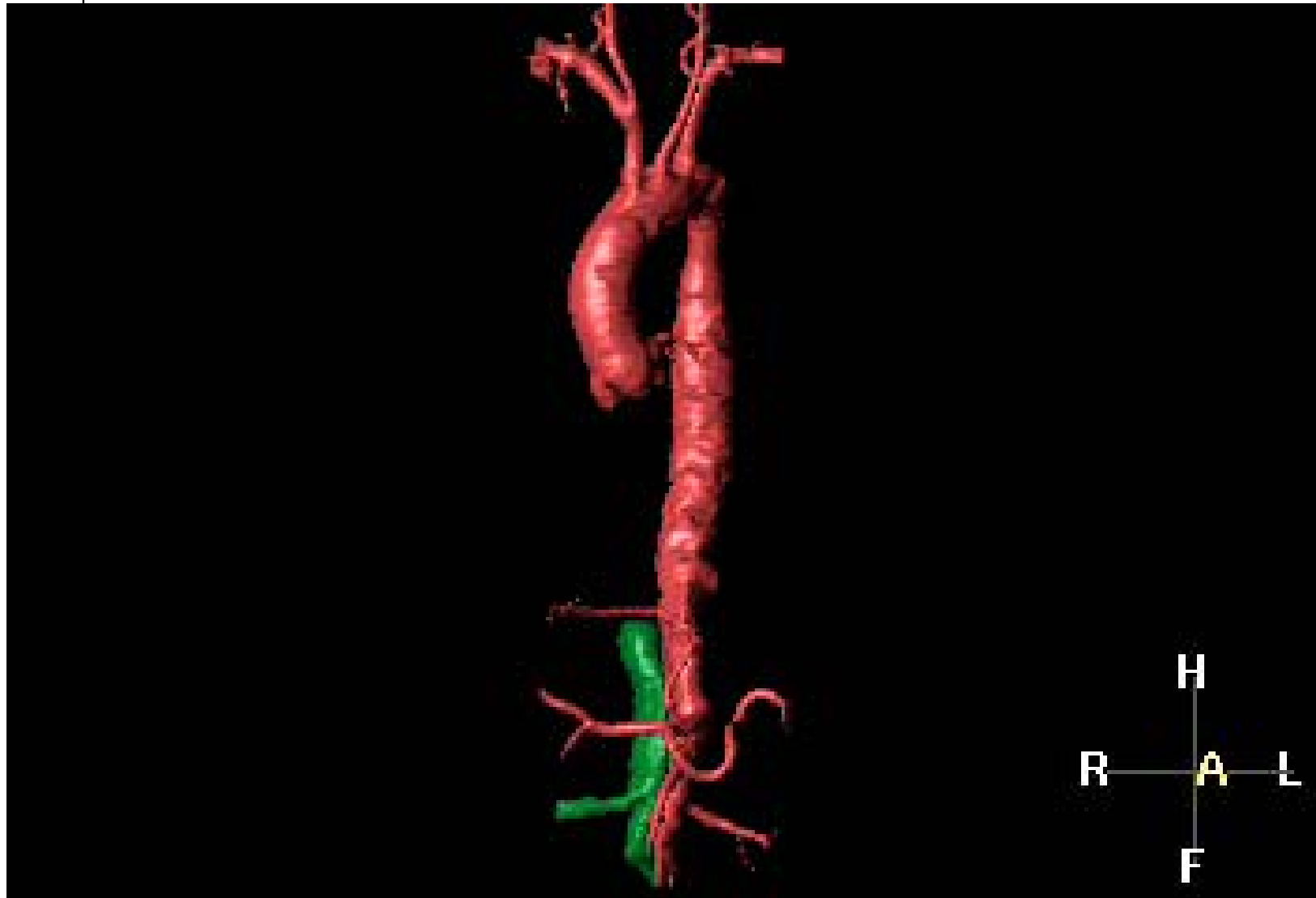## Intraluminal Suturing of the Dacron Prosthesis



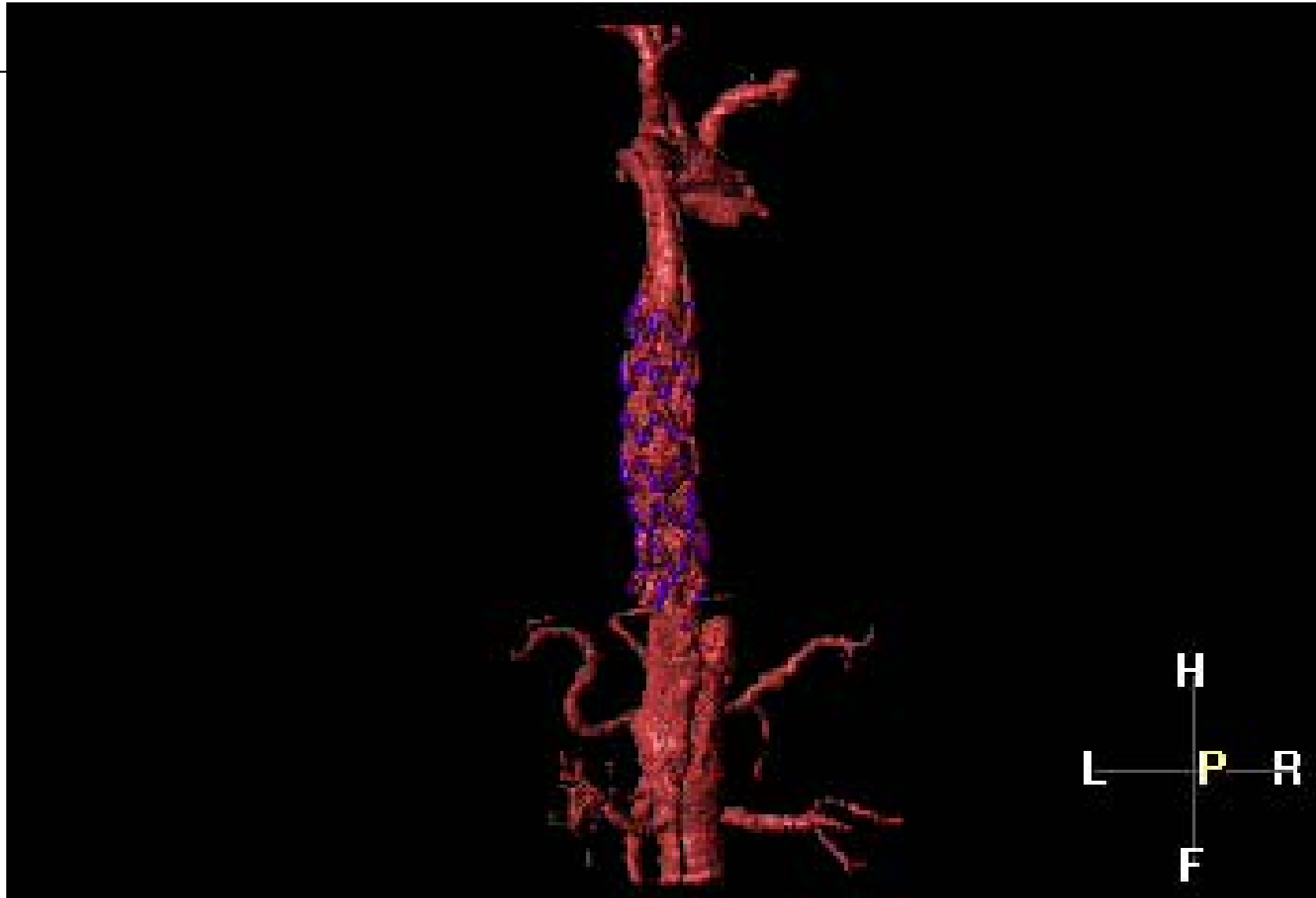
## Angio-MRI: Result

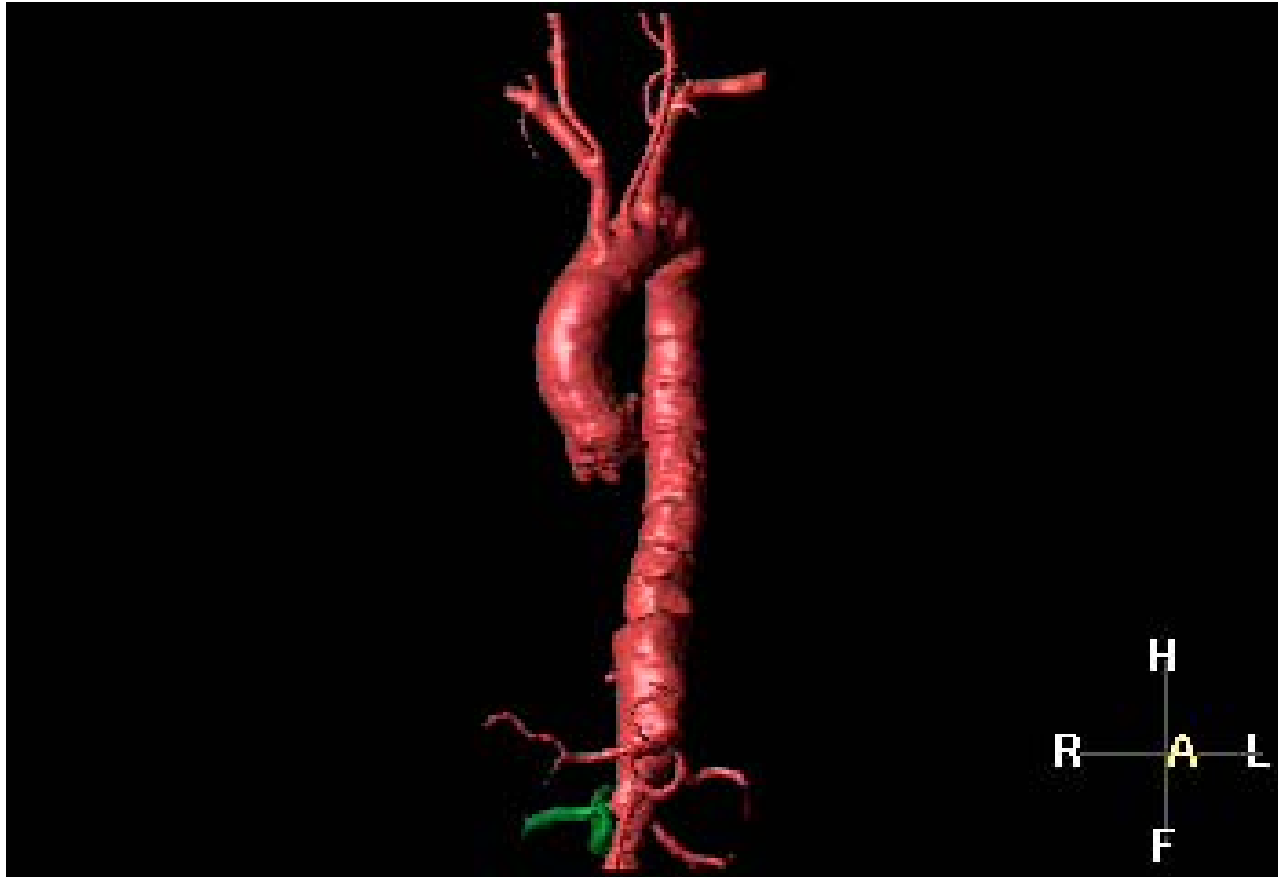

## MRI: Result



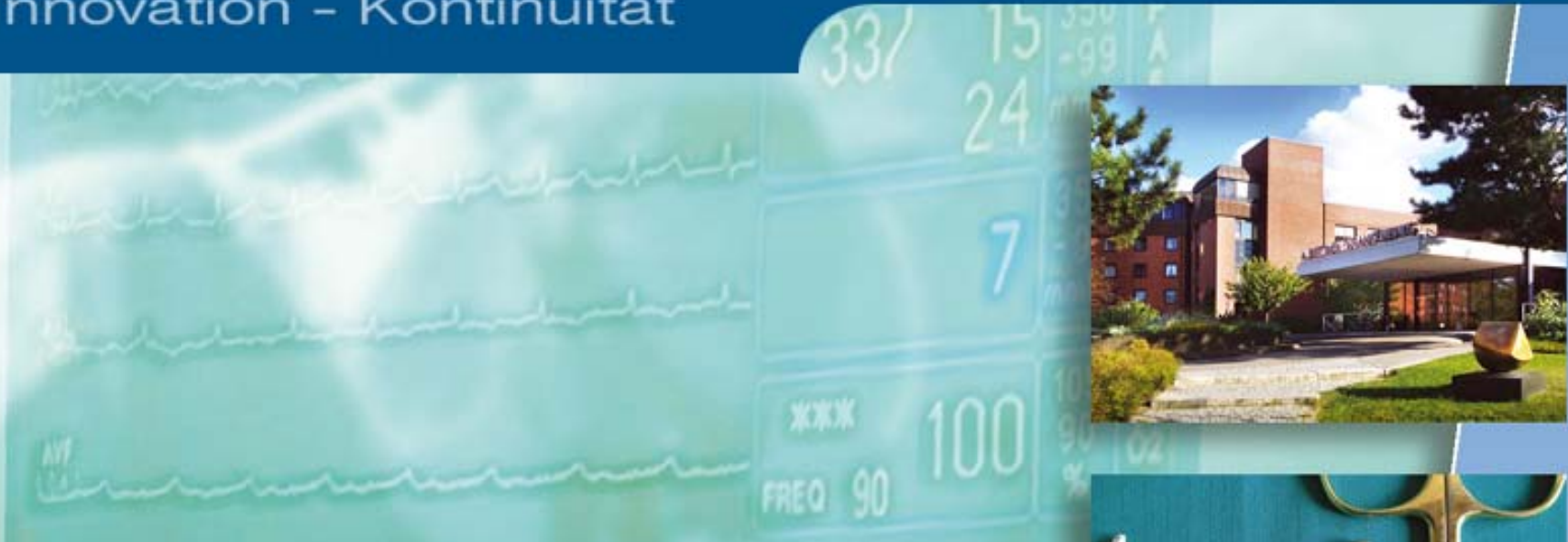## CT: Stent



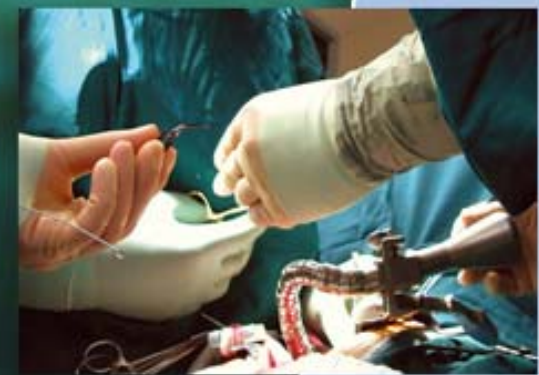

## Stenting of Descending Aorta (4 Month post OP)

Qualität - Innovation - Kontinuität



**Danke für Ihre Aufmerksamkeit!**



## Impressum

Priv.-Doz. Dr. F.-C. Rieß  
Albertinen-Herzzentrum  
Süntelstraße 11 a  
22457 Hamburg

[www.albertinen.de](http://www.albertinen.de)

© 2005